

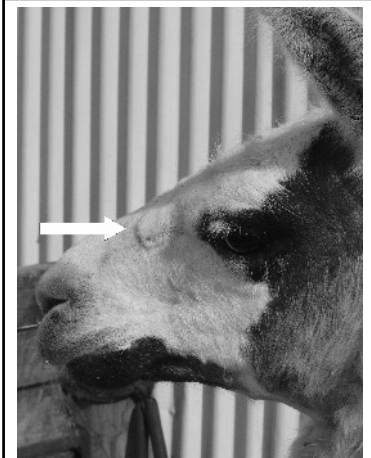# Ringworm

My experiences, Julie Insley

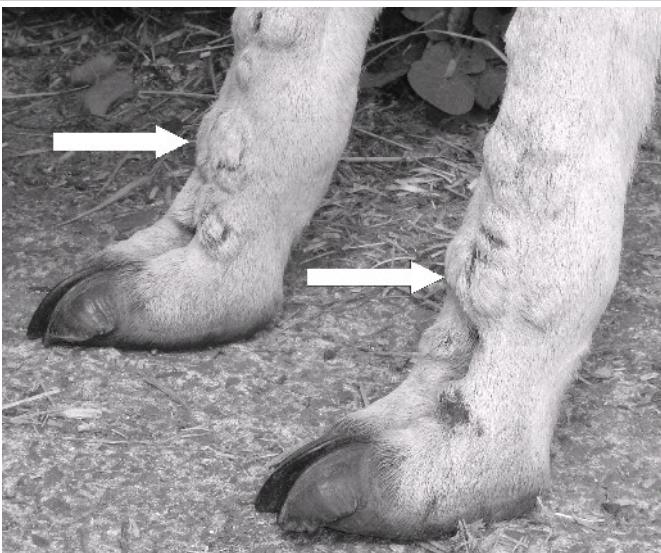
**What is Ringworm?** (Dermatophytosis) Two dermatophytes have been isolated from llamas. *Trichophyton verrucosum* is the common cause of ringworm and *T. mentagrophytes* var. *mentagrophytes*. These are fungi that grow in the hair and hair follicle. Not an actual worm or parasite.

**Diagnosis:** Your vet can confirm diagnosis with a culture or a microscopic exam.

**Spread:** By direct and indirect contact. Skin and hair that falls off while infected may remain viable for years attached to barn walls, fence posts, trees, feed dishes, halters and brushes.



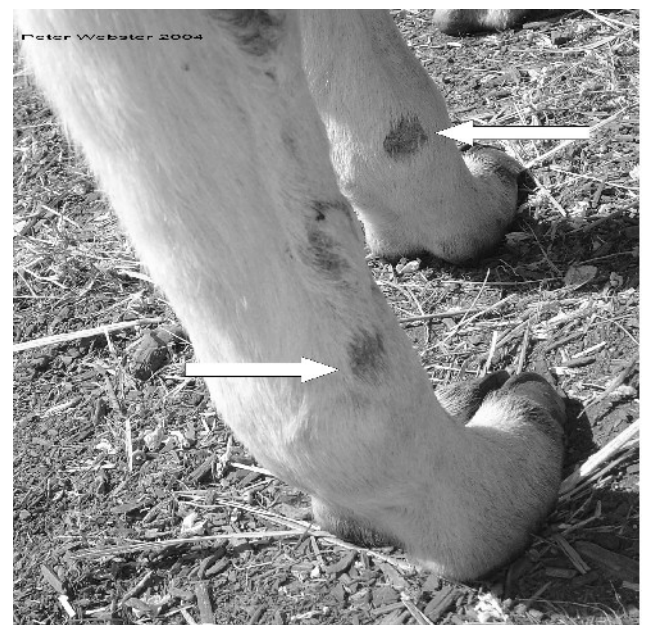Usually located on the head, base of ears and feet.



**Clinical signs:** Lesions with raised, crusty, circular patches that turn into bald spots. As indicated by the white arrows. The llama may be trying to rub or scratch them.

**Observations:** Virtually every llama that has come to my property (Bay of Islands, Far North) from the South Island has developed ringworm at some time, this usually occurs about eight weeks after they arrive. All llamas born here get it at a few months old. They all only appear to get it one time. Younger llamas appear to get it more severely than older llamas. The llamas appear unfazed by the condition and there have never been any long-term effects.

**Treatment:** It can be easily treated with topical Betadine or Iodine applied to the area. Diluted Copper Sulphate can be sprayed on. You can also use human antibiotic creams such as Daktarin or Bactroban as they work well. I have also heard that dabbing on tea tree oil will work. If it does not respond within a few weeks seek Veterinarian help to ensure it is not Mud Fever or Mange. It is contagious to other animals and people - wash your hands well after treatment.



**Bottom photo** taken 16 days later than top photo, note the scabs have started lifting off. One month later the hair was grown back.